

## A Very Rare Adverse Effect of Clozapine, Clozapine-induced Interstitial Lung Disease: Case Report and Literature Review

### Klozapine Bağlı İnterstisyel Akciğer Hastalığı–Nadir Görülen Bir Advers Etki: Olgu Sunumu ve Literatür Taraması

Kazım Cihan CAN<sup>1</sup> , Demet KARNAK<sup>2</sup> , Halise DEVRİMCİ ÖZGÜVEN<sup>1</sup> 

<sup>1</sup>Department of Psychiatry, Ankara University School of Medicine, Ankara, Turkey

<sup>2</sup>Department of Chest Diseases, School of Medicine, Ankara University, Ankara, Turkey

#### ABSTRACT

Clozapine is the gold-standard antipsychotic agent for treatment-resistant schizophrenia. Yet with all its clinical efficacy, there are numerous adverse effects associated with clozapine. Although many, such as leucopenia and agranulocytosis, are well established, there is little published material on the drug's rare adverse effects. Among these,

very little is known about clozapine-induced interstitial lung disease. Here we present such a case. We focus on its clinical aspects and discuss its relationship to the extant literature.

**Keywords:** Clozapine; interstitial lung disease; schizophrenia

#### ÖZ

Klozapin, tedaviye dirençli şizofreninin tedavisinde altın standart antipsikotik ilaçtır. Klinik etkinliğinin yanında, klozapin ile ilişkilendirilen sayısız yan etki bildirilmiştir. Lökopeni ve agranülositoz gibi bazı yan etkileri iyi bilinmesine rağmen, klozapin ile ilişkili bazı nadir yan etkiler hakkında yayımlanmış çok az veri bulunmaktadır. Bu nadir yan etkiler

arasında klozapin ile indüklenmiş interstisyel akciğer hastalığı hakkında çok az şey bilinmektedir. Bu yazıda, bir klozapin ile indüklenmiş akciğer hastalığı vakasını klinik özellikleri ve literatür gözden geçirmesi ile beraber sunuyoruz.

**Anahtar Kelimeler:** Klozapin; interstisyel akciğer hastalığı; şizofreni

**Cite this article as:** Can KC, Karnak D, Özgüven HD. A Very Rare Adverse Effect of Clozapine, Clozapine-induced Interstitial Lung Disease: Case Report and Literature Review. Arch Neuropsychiatry 2019;56:313-315.

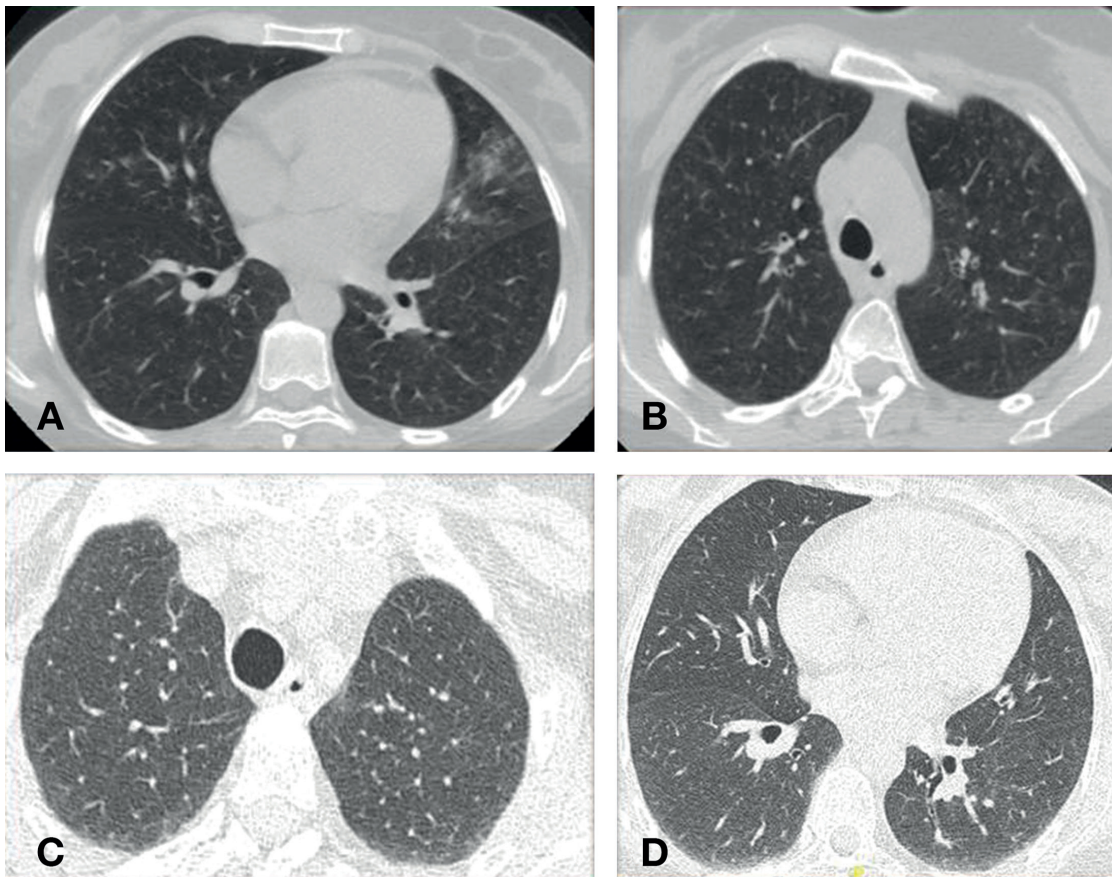
#### INTRODUCTION

Clozapine is the gold standard antipsychotic agent for addressing treatment-resistant schizophrenia. Despite its efficacy and better clinical outcomes in terms of positive and negative symptoms, there are numerous adverse effects associated with clozapine (1). Although some adverse effects, such as leucopenia and agranulocytosis, are well established, little has been published on rare adverse effects associated with clozapine. Among these effects, very little is known about clozapine-induced interstitial lung disease. Drug-induced lung disease (DI-ILD) is a diagnostic challenge due to its nonspecific clinical presentation (2). The diagnosis relies upon: a) an association between exposure and the subsequent development of symptoms; b) lung infiltrates; c) the exclusion of other causes, and d) symptom resolution once the agent is withdrawn (3). To date, there have been only a few case reports in the literature (2, 4–7). Here, we present a case of clozapine-induced interstitial lung disease, and discuss it both in terms of clinical experience and its relationship to extant medical literature. Written informed consent was obtained from the patient for publication.

#### CASE REPORT

A 39-year-old female with a history of schizophrenia applied to our clinic for routine outpatient clinic examination with symptoms of fever, fatigue, productive coughing and shortness of breath. The patient had a medical history of treatment-resistant schizophrenia, bronchial asthma and allergic rhinitis. Her daily medication consisted of clozapine 300 mg/d, fluoxetine 20 mg/d, Fluticasone propionate/salmeterol 500 mg/d and montelukast 10 mg/d. She had been undergoing clozapine treatment for 10 years. The decision to start clozapine treatment was taken due to the fact that she had treatment-resistant symptoms and was a high suicide risk. After clozapine treatment, she achieved nearly full remission from psychotic symptoms, became free of suicide risk, and she had a good social functioning. After full remission was achieved, she regularly attended our outpatient rehabilitation therapy groups.

In June 2016, the patient mentioned shortness of breath in her regular psychiatric visit. Her dyspnea was moderate and she was able to ambulate without difficulty. Her physical examination was only remarkable for bilateral rhonchi and fine crepitation. The patient was an ex-smoker for five years with a 15 pack-year smoking history. She was diagnosed with



**Figure 1.** a-d. High resolution computed chest tomography (HRCT) of the patient with bilateral micronodular and diffuse patched ground glass opacities (a, b). Nearly total resolution of infiltrates in HRCT is seen (c, d).

bronchial asthma and allergic rhinitis for five years and was referred to the pulmonology department of our university hospital. Laboratory tests revealed mild elevated C-reactive protein (21.6 mg/L; reference, 0–5.0 mg/L), and mild leukocytosis ( $15.25 \times 10^9/L$ ; reference,  $4.5\text{--}11 \times 10^9/L$ ). There was no peripheral eosinophilia. Liver and renal function tests were normal, as was the echocardiography. Urine tests were negative. Pulmonary function test results revealed a restrictive pattern ( $FEV_1$  75% ;  $FEV_1/FVC$  83%,  $FEV_2/FVC$ : 75 and DLCO: 60%). A chest X-ray and a high resolution computed chest tomography (HRCT) revealed bilateral micronodular and diffuse patched ground glass opacities (Figure 1. a, b). This was initially diagnosed as pneumonia, and amoxicillin clavulanate 1000 mg was administered for 14 days. No clinical improvement was observed, and macrolides and quinolones were further prescribed, without results. Thus, DI-ILD was suspected as a diagnosis. Clozapine was determined as the most liable medication for the patient's remission. By virtue of its criticality, fluoxetine hence was discontinued and prednisolone 5 mg/d was initiated. Although her complaints were partially alleviated after three months of medication, the cessation of prednisolone exacerbated pulmonary symptoms. Follow-up chest X-rays and an HRCT showed newly developing bilateral diffuse patched ground glass opacities—these were in addition to the prior resolved opacities—as compared to previous HRCT. Her pulmonary complaints were moderate and did not necessitate hospitalization. We then began a high dose of fluticasone (2000 micrograms). The discontinuation of fluoxetine led to no improvement. We thus planned to discontinue the use of clozapine, not abruptly but as a cross-titration with another antipsychotic agent, quetiapine. We envisioned this process of cross-titration over a six-week period and reduced the patient's clozapine dose to 50 mg/w, and increased the quetiapine dose of 100 mg/w to 600 mg/d. After the cessation of clozapine, the patient continued with a dose of 600 mg of quetiapine daily for 12 weeks, along with tapered doses of methylprednisolone (7–10 mg). The patient's pulmonary symptoms were fully alleviated. A third follow-up HRCT showed near total resolution of infiltrates in comparison

with previous HRCTs. We hereby confirmed with certainty our diagnosis of clozapine-induced interstitial lung disease (Fig. 1. c, d). After treatment, diffusion capacity and pulmonary function tests returned entirely to normal, along with improved diffusion capacity ( $FEV_1$  82% ;  $FEV_1/FVC$  89%,  $FEV_2/FVC$ : 83 and DLCO: 79%). However, the patient gradually developed psychotic symptoms, including referential and persecution delusions, auditory hallucinations, thought broadcasting, and suicidal thoughts. As psychotic symptoms had not been alleviated during a 600 mg daily regimen of quetiapine, we changed her antipsychotic therapy to a treatment regime consisting of olanzapine 30 mg/d and sulpiride 50 mg/d. The patient's auditory hallucinations and thought broadcasting disappeared, but her referential and persecution delusions continued, though at decreasing levels. She was not able to function as previously under clozapine treatment.

## DISCUSSION

This report describes a case of drug-induced interstitial lung disease due to clozapine administration. On the basis of mild-to-moderate clinical symptoms, as well as laboratory and radiological findings, we suspected that the patient had community-acquired or aspiration pneumonia. Hence, we administered empirical antibiotic treatment at the first step. As the patient's clinical symptoms showed no improvements, after re-evaluation of the case, the diagnosis of DI-ILD was established.

A literature review shows, to our knowledge, only five cases of DI-ILD with clozapine (2, 4–7) and three cases with fluoxetine (8–10). Even though DI-ILD has been reported more with clozapine than fluoxetine, due to the fact that clozapine was the main treatment of the patient and her pulmonary symptoms were mild to moderate, we initially decided to cease fluoxetine treatment. Follow-up radiological examinations showed no improvement related to our findings. All this led us to the only probable

agent: clozapine. After the cessation of clozapine, the patient's clinical symptoms and radiological findings improved rapidly, thus making clear the diagnosis of this case as clozapine-induced lung disease. Rapid clinical improvement and full recovery of DI-ILD in our patient is consistent with three of five reported cases in the literature (2, 5, 7). Arias, Cohen and Kwon reported clinical improvement and chest CT confirmed resolutions of infiltrates, with no other changes than the discontinuation of clozapine in their case (2). Aldridge et al. reported on a 77 years old man with clozapine-induced pneumonitis. They reported that discontinuation of clozapine also ameliorated the patient's respiratory symptoms, although the patient continued to require treatment for cardiac failure (4). Lastly, Bugge et al. reported on a case of clozapine-induced lung disease and perimyocarditis (6). Consistent with other cases in the literature and with the case we present here, the cessation of clozapine normalized chest X-ray findings, yet ventricular hypokinesia and low ejection fraction rates persisted in their case (6).

Most of the cases of interstitial pneumonia during clozapine therapy are due to aspiration (11). This complication can occur at any period during clozapine therapy (1). That said, all of the five reported clozapine-induced lung disease cases' symptom onsets were at the initial phase of clozapine treatment. Hashimoto et al. (7) described the 13rd day of the initiation of clozapine treatment. Other cases were similar: the 15th day (5), the 20th (4), approximately one week after (6), or two months after (2). We report here a case that developed DI-ILD 10 years after clozapine treatment. To our knowledge, this is the first such reported case in the literature. We considered this as a rather rare clozapine adverse effect, which may be more recognizable in its initial phases, especially in the first 18 weeks, and related to intense follow-ups for early agranulocytosis risk. Although some adverse effects of clozapine occur early in treatment, clinicians must be aware of possible rare adverse effects, even in long-term follow-ups.

Drugs can produce virtually all histopathological patterns of interstitial pneumonia (3). But most cases do not undergo a confirmatory lung biopsy, which makes it more difficult to infer the histopathological background of DI-ILDs (12). The diagnosis of drug-induced lung diseases rests on the notion of a definite temporal association between exposure to the agent and the development of respiratory signs and symptoms (3). Our case's clinical symptoms were mild, and she was ambulatory. Also, the patient responded well to drug withdrawal and steroids. Considering this, we felt that we were on the right clinical path. Therefore, neither a lung biopsy nor a bronchoalveolar lavage was performed in this case. Consequently, we do not know the histopathological diagnosis. However, diffuse ground-glass opacities and small nodular patterns appeared in our case's Chest X-ray and HRCT findings, all of which ceased with treatment. After the discontinuation of inhaled and oral steroids, no recurrence was observed to support the correct diagnosis. Although this might be considered as a limitation for differential diagnosis, lung biopsy or bronchoalveolar lavage may not be necessary for the diagnosis of DI-ILD (3). Eosinophilic lung diseases such as acute and chronic eosinophilic pneumonia, Loeffler pneumonitis, Churg Strauss Syndrome and allergic bronchopulmonary aspergillosis were also excluded due to a lack of normal peripheral eosinophil counts and radiological pattern.

Very little is known about the pathophysiological mechanisms of DI-ILDs. A possible allergic reaction to clozapine was discussed as a pathophysiological mechanism underlying this condition in three of the five case reported in the literature. Elevated serum eosinophil levels have been reported in three cases (5–7). Two further case reports mentioned normal serum eosinophil levels, as in the case we report here (2, 4). We

evaluated, in this work, allergic reaction as an unlikely etiology with regard to normal serum eosinophil levels or a late onset of respiratory symptoms. Considered as a whole, an allergic reaction to clozapine seems one of the possible explanations for the pathophysiology of DI-ILD but not only.

This case points to the importance of careful medical monitoring, not only during clozapine initiation but also across the long-term follow-up of patients taking clozapine. Non-specific respiratory symptoms such as shortness of breath, low-grade fever, cough and fatigue may indicate a rare but serious adverse effect. Because DI-ILD is a diagnosis of exclusion, clinicians should be attentive to the complaints of patients and suspicious of rare adverse effects to rule out such adverse effects.

**Peer-review:** Externally peer-reviewed.

**Informed Consent:** Written informed consent was obtained from the patient.

**Author Contributions:** Concept - KCC, HDÖ; Design - KCC, HDÖ; Supervision - KCC, DK, HDÖ; Resource - KCC, DK, HDÖ; Materials - KCC, DK, HDÖ; Data Collection and/ or Processing - KCC, DK, HDÖ; Analysis and/ or Interpretation - KCC, DK, HDÖ; Literature Search - KCC, DK, HDÖ; Writing - KCC, DK, HDÖ; Critical Reviews - KCC, DK, HDÖ.

**Conflict of Interest:** No conflict of interest was declared by the authors.

**Financial Disclosure:** The authors declared that this study has received no financial support.

**Hakem Değerlendirmesi:** Dış Bağımsız.

**Hasta Onam:** Yazılı hasta onamı alınmıştır.

**Yazar Katkıları:** Fikir - KCC, HDÖ; Tasarım - KCC, HDÖ; Denetleme - KCC, DK, HDÖ; Kaynak - KCC, DK, HDÖ; Malzemeler- KCC, DK, HDÖ; Veri Toplanması ve/veya İşlemesi - KCC, DK, HDÖ; Analiz ve/ veya Yorum - KCC, DK, HDÖ; Literatür Taraması - KCC; Yazıyı Yazan - KCC, DK, HDÖ; Eleştirel inceleme - KCC, DK, HDÖ.

**Çıkar Çatışması:** Yazarlar çıkar çatışması olmadığını beyan etmişlerdir.

**Finansal Destek:** Yazarlar bu çalışma için finansal destek almadıklarını beyan etmişlerdir.

## REFERENCES

1. Guith DM. Clozapine: serious adverse side effects, drug interactions, and other complications of therapy. *J Pharm Pract* 1996;9:118–129. [CrossRef]
2. Arias SA, Cohen P, Kwon JS. Clozapine-induced lymphocytic alveolitis. *Am J Psychiatry* 2011;168:210–211. [CrossRef]
3. Camus P, Fanton A, Bonniaud P, Camus C, Foucher P. Interstitial lung disease induced by drugs and radiation. *Respiration* 2004;71:301–326. [CrossRef]
4. Aldridge G, Collins C, Croucher M. Clozapine-induced pneumonitis. *Aust New Z J Psychiatry* 2013;47:1215–1216. [CrossRef]
5. Benning TB. Clozapine-induced extrinsic allergic alveolitis. *Br J Psychiatry* 1998;173:440–441. [CrossRef]
6. Bugge E, Nissen T, Wynn R. Probable clozapine-induced parenchymal lung disease and perimyocarditis: a case report. *BMC Psychiatry* 2016;16:438. [CrossRef]
7. Hashimoto N, Maeda T, Okubo R, Narita H, Kusumi I. Simple pulmonary eosinophilia associated with clozapine treatment. *J Clin Psychopharmacol* 2015;35:99–101. [CrossRef]
8. Braun D, Nippert B, Loeuille D, Blain H, Trechot P. Interstitial pneumopathy induced by fluoxetine. *Rev Med Interne* 1999;20:949–950. [CrossRef]
9. de Kerviler E, Tredaniel J, Revlon G, Groussard O, Zalcmán G, Ortoli JM, Espié M, Hirsch A, Fria J. Fluoxetine-induced pulmonary granulomatosis. *Eur Respir J* 1996;9:615–617. [CrossRef]
10. Gonzalez-Rothi RJ, Zander DS, Ros PR. Fluoxetine hydrochloride (Prozac)-induced pulmonary disease. *Chest* 1995;107:1763–1765. [CrossRef]
11. Abdelmawla N, Ahmed MI. Clozapine and risk of pneumonia. *Br J Psychiatry* 2009;194:468–469. [CrossRef]
12. Zompatori M, Bnà C, Poletti V, Spaggiari E, Ormitti F, Calabrò E, Tognini G, Sverzellati N. Diagnostic imaging of diffuse infiltrative disease of the lung. *Respiration* 2004;71:4–19. [CrossRef]