

A Rare Cause of Neuropathic Pain in the Back: Notalgia Paresthetica

Rabia TERZİ¹, Pınar BEKDİK ŞİRİNOCAK²

¹Clinic of Physical Medicine and Rehabilitation, Derince Training and Research Hospital, Kocaeli, Turkey

²Clinic of Neurology, Derince Training and Research Hospital, Kocaeli, Turkey

Dear Editor,

Notalgia paresthetica (NP) is a neuropathy with unknown cause of thoracic spinal nerves T2-T6, particularly their dorsal branches. It is a chronic disease that can be seen among the elderly and females. Despite its unknown etiology, NP is thought to result from posterior spinal nerve impingement or chronic nerve trauma. In addition, increased dermal innervation and viscera-cutaneous reflex mechanisms are other mechanisms responsible for their chemical neurotoxicity. It is a clinical condition associated with a character of neuropathic pain, itching, and nonspecific skin lesions with brown pigment in both the dorsal vertebrae and scapular areas (1).

A 69-year-old male patient with pain in the dorsal region was admitted to our clinic with complaints of itching, stinging, and burning. He stated that his complaints had existed for 6 months. In his medical history, there was no disease other than hypertension. On physical examination, it was observed that there was a hyperpigmented skin lesion of approximately 5 × 6 cm in diameter at the lateral right scapula of the dorsal region (Figure 1). Thoracal kyphosis had increased. At the lower part of the right trapezius muscle, tense bands were evident. It was observed that the range of motion of the cervical joint was normal, but rotations were painful. Hypoesthesia was present in the region where skin lesion also existed. Dorsal paravertebral muscle spasm was also present. The patient's laboratory tests were normal. Degenerative changes were detected in the cervical and dorsal radiographic and MRI examinations. There were no traces of any spinal nerve compression. In the needle EMG, no abnormal finding was observed. Dermatology consultation for skin lesion confirmed the diagnosis of NP. As a treatment, 900 mg/day gabapentin was initiated and increased gradually. Transcutaneous electrical nerve stimulation (TENS) (10 mA, 50 Hz, 50 µs for 20 min) was applied, and isometric, joint range of motion, and strengthening exercises were intermittently given to the cervical and dorsal vertebral region for 10 days. In the first month of treatment, there was significant improvement in the patient's clinical condition. Informed consent was obtained from the patient who participated in this case.

The spinal nerve entrapment that occurred in NP may be associated with degenerative changes in the spine, paraspinal muscle spasm, or fibrous bands (2). In the study of Savk et al. (3), the localization of symptoms in approximately 60% of patients and an overlap between radiological findings such as degenerative vertebral changes support the contribution of spinal nerve trauma to pathogenesis. On physical examination of our patient, the presence of fibrous bands and degenerative changes in the cervical and dorsal regions was considered to have been the primary foundation of the disease.

In these cases, electrodiagnostic findings are diverse. In EMG, while there are patients who underwent denervation of paraspinal muscles with positive waves, patients with normal findings have also been reported (4,5). EMG in our patient was found to be normal.

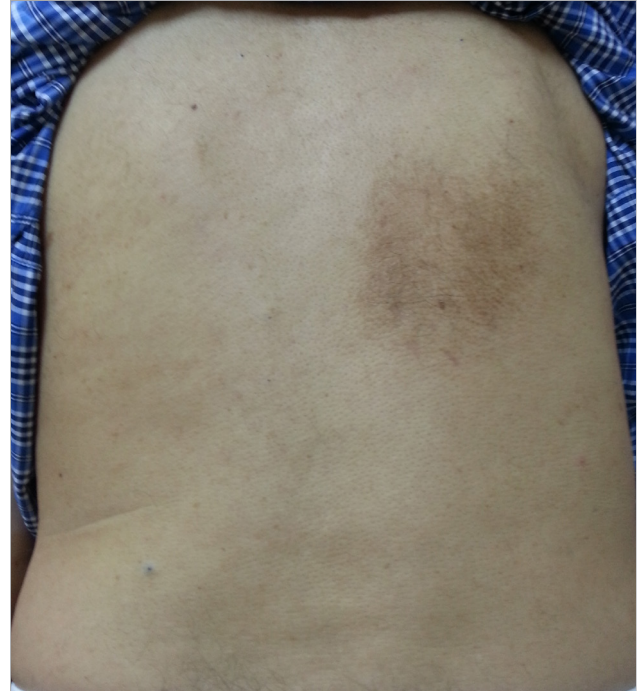


Figure 1. Hyperpigmented skin lesions in the lateral right scapula



Correspondence Address: Rabia Terzi, Derince Eğitim ve Araştırma Hastanesi, Fiziksel Tıp ve Rehabilitasyon Kliniği, Kocaeli, Türkiye
E-mail: drrabia1@yahoo.com

Received: 01.11.2014 **Accepted:** 18.11.2014

©Copyright 2016 by Turkish Association of Neuropsychiatry - Available online at www.noropsikiyatrisivi.com

In NP treatment, topical anesthetics, topical capsaicin, intralesional corticosteroid, and botulinum toxins are preferred local treatment applications. Gabapentin, oxcarbazepine, amitriptyline, paravertebral local anesthetic blocks, spinal manipulation, and physical therapy applications are other treatment options (6).

Because of frequent neuropathic pain, these patients can be referred to clinics other than dermatology, offering physical therapy and rehabilitation services. They can also be referred to neurology and algology clinics. A multidisciplinary approach toward these patients is of major importance. In these patients, gabapentin, physical therapy applications, and spinal vertebral pathologies associated with lesion bring about a curative result.

Conflict of Interest: No conflict of interest was declared by the authors.

Financial Disclosure: The authors declared that this study has received no financial support.

REFERENCES

1. Raison-Peyron N, Meunier L, Acevedo M, Meynadier J. Notalgia paresthetica: Clinical, physiopathological and therapeutic aspects. A study of 12 cases. *J Eur Acad Dermatol Venereol* 1999; 12:215-221. [\[CrossRef\]](#)
2. Ellis C. Notalgia paresthetica: the unreachable itch. *Dermatol Pract Concept* 2012; 3:2.
3. Savk O, Savk E. Investigation of spinal pathology in notalgia paresthetica. *J Am Acad Dermatol* 2005; 52:1085-1087. [\[CrossRef\]](#)
4. Marcusson JA, Lundh B, Sidén A, Persson A. Notalgia paresthetica--puzzling posterior pigmented pruritic patch. Report on two cases. *Acta Derm Venereol* 1990; 70:452-454.
5. Massey EW, Pleet AB. Electromyographic evaluation of notalgia paresthetica. *Neurology* 1981; 31:642. [\[CrossRef\]](#)
6. Pérez-Pérez LC. General features and treatment of notalgia paresthetica. *Skinmed* 2011; 9:933-939.