

Clinical and Electrophysiological Findings in Two Siblings with Familial Hyperekplexia

Ailesel Hiperekpleksi Olan İki Kardeşte Klinik ve Elektrofizyolojik Bulgular

Yeşim GÜLEN ABANOZ, Yasin ABANOZ, Ayşegül GÜNDÜZ, Nurten UZUN, Meral E. KIZILTAN

Department of Neurology, İstanbul University Cerrahpaşa School of Medicine, İstanbul, Turkey

Dear Editor,

Hyperekplexia is a rare hereditary or symptomatic disorder with an abnormal response to unexpected auditory, visual, or tactile stimuli (1). Diagnosis of hyperekplexia is generally delayed because of misdiagnosis such as seizures. Clonazepam is suggested to be the most effective treatment option.

Here, we report the role of neurophysiological findings and the effectiveness of levetiracetam in two siblings who presented with the classical clinical phenotype of hyperekplexia.

Patient 1: A 25-year-old woman was admitted with drop attack-like episodes that appeared after unexpected stimuli. She suffered from severe injuries because of frequent falls owing to stiff legs without the loss of consciousness and had insecure gait because of the fear of falling. She had freezing of gait while walking in wide halls but walked more comfortably in narrow corridors. She also had spasms on the lower limbs and emotional stress. Her legs were not stiff when she was a baby. During childhood, she was treated with carbamazepine and valproic acid cycles but achieved only partial clinical response. Although she discontinued medication during her pregnancy, she claimed that her complaints improved. Neurological examination was unremarkable, except for increased deep tendon reflexes.

Patient 2: A 42-year-old man, brother of Patient 1, also had the same clinical symptoms. He suffered from excessive startle responses and hypnic jerks since the age of 5 years and had several spontaneous spasms and injuries because of frequent drop attack-like episodes, similar to his sister. However, he was not affected by consecutive similar loud noises such as those while riding a motorcycle. He previously used carbamazepine, phenytoin, and phenobarbital. Neurological examination was unremarkable.

Routine biochemical test results, electroencephalography, and cranial magnetic resonance imaging were all normal in both patients. Their parents were first-degree relatives. Moreover, four other family members had the same clinical symptoms. First, we performed motor and sensory nerve conduction studies and needle electromyography, results of which were normal. Second, we studied responses of orbicularis oculi (O.oc), masseter, sternocleidomastoid (SCM), biceps brachii, abductor pollicis brevis (APB), and tibialis anterior muscles after supraorbital electrical stimuli, auditory stimuli (auditory startle reflex, ASR), and electrical stimuli of the median nerve at the wrist (startle reflex to somatosensory inputs, SSS). The patients and their relatives gave informed consent for the tests.

Both components of the trigeminal blink reflex (TrBR) were obtained with normal forms and latencies. However, supraorbital stimulation led to more widespread responses in areas such as muscles of upper and lower extremities. ASR response was first obtained in O.oc muscles, followed by masseter, SCM, biceps brachii, APB, and tibialis anterior muscles. However, probability of ASR on caudal muscles was high and ASR did not habituate. Response rates of all muscles examined were 100%. We did not observe any habituation even after investigating with stimuli of low duration. Somatosensory electrical stimulus, which was capable of stimulating the motor response in APB muscles, resulted in responses in all recorded bulbar and proximal and distal extremity muscles in both patients. Figure 1 shows examples of electrophysiological findings of Patient 1. Latencies were also much shorter in both patients. The values of each patient are shown in Table 1.

Administering levetiracetam at increasing doses from 500 to 1500 mg/day led to obvious clinical improvement. We observed that exaggerated startle responses and stiffness of legs following startle reduced with the treatment. Electrophysiological findings revealed the less generalized development of ASR habituation after administering levetiracetam; however, latencies did not change.

In this report, we described the electrophysiological findings of familial hyperekplexia and the effect of levetiracetam on both clinical and electrophysiological findings.



Correspondence Address / Yazışma Adresi: Ayşegül Gündüz, İstanbul Üniversitesi Cerrahpaşa Tıp Fakültesi, Nöroloji Anabilim Dalı, İstanbul, Türkiye
E-mail / E-posta: draysegulgunduz@yahoo.com

Received / Geliş tarihi: 02.11.2015 • **Accepted / Kabul tarihi:** 08.01.2016

©Copyright 2017 by Turkish Association of Neuropsychiatry - Available online at www.noropskiyatrisivi.com

©Telif Hakkı 2017 Türk Nöropsikiyatri Derneği Makale metnine www.noropskiyatrisivi.com web sayfasından ulaşılabilir.

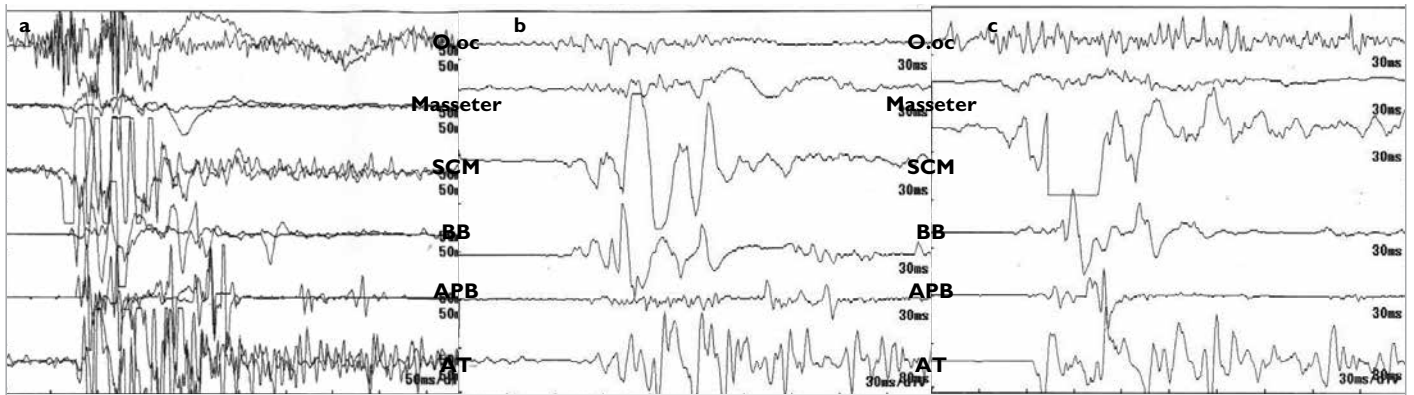


Figure 1. a-c. Reponses of patient I after auditory stimuli (a), somatosensory stimuli (b), and trigeminal stimuli (c), which were generalized. Auditory startle response did not show habituation with repeated stimuli

O.oc: orbicularis oculi; SCM: sternocleidomastoid; BB: biceps brachii; APB: abductor pollicis brevis; AT: anterior tibialis muscles.

Table 1. Latencies of reflexes obtained after auditory, somatosensory, and trigeminal stimuli

	Auditory stimulation (ASR)			SS stimulation			Trigeminal stimulation		
	Patient 1	Patient 2	Lab normal n=11	Patient 1	Patient 2	Lab normal n=11	Patient 1	Patient 2	Lab normal n=11
O.oc	28.0	41.0	32.0±3.8	62.0	39.0	46.8±9.5	10.2-33	10.8- 36.0	10.5-31.5 (BR)
Mas.	60.0	64.0	70.0±17.0	87.0	NR	NR	45.0	NR	NR
SCM	50.0	56.0	74.0±23.5	60.0	44.0	92.9±34.8	14-41.2	80	17.0-57.8 (TCR)
BB	67.0	63.0	84.0±7.0	76.0	60.0	107.7±58.3	57	82	NR
APB	80.0	76.0	NR	113.0	NR	NR	70	NR	NR
AT	82.0	91.0	NR	93.0	72.0	NR	66.6	101.0	NR

APB: abductor pollicis brevis; AT: anterior tibialis; BB: biceps brachii; BR: blink reflex; NR: no response; Mas: masseter; O.oc: orbicularis oculi; SCM: sternocleidomastoid; TCR: trigeminocervical reflex; SS: somatosensory stimulation

Hyperekplexia, which has a “major” or “minor” form, is one of the three heterogeneous groups of disorders with abnormal responses to startling events (1). Our patients may be categorized as having the major form, which is characterized by exaggerated startle reaction and generalized muscular stiffness starting in the childhood and progressively decreasing as the child grows. Stimulus required to induce a startle reaction should be unexpected and sudden. As observed in Patient 2, consecutive similar stimuli did not induce startle; thus, he was able to ride the motorcycle.

Polymyographic electrophysiological study should be considered in the diagnosis of exaggerated startle reflex (1). The startle responses after different types of stimuli are hyperexcitable in hyperekplexia (2,3,4). The observations of increased responsiveness in our patients supported the diagnosis. Normal latencies enabled the exclusion of structural lesions as the cause of hyperekplexia in our patients.

Although the exact mechanism of levetiracetam remains unknown, its antemyoclonic effect may be related to the blockade of gamma amino butyric acid A (GABA_A) receptor modulators (5). Intrathecal baclofen decreases brainstem reflexes: both R2 component of TrBR and ASR which is attributed to the GABAergic activity (6). The effectiveness of levetiracetam, both in clinical and electrophysiological findings, is probably because of GABA receptors at the brainstem level.

In patients with unexplained falls, hyperekplexia should be included in the differential diagnosis, and levetiracetam may be used.

Conflict of Interest: No conflict of interest was declared by the authors.

Financial Disclosure: The authors declared that this study has received no financial support.

Çıkar Çatışması: Yazarlar çıkar çatışması bildirmemişlerdir.

Finansal Destek: Yazarlar bu çalışma için finansal destek almadıklarını beyan etmişlerdir.

REFERENCES

- Bakker MJ, van Dijk JG, van den Maagdenberg AM, Tijssen MA. Startle syndromes. *Lancet Neurol* 2006; 5:513-524.
- Oguro K, Hirano K, Aiba H. Trigeminal induced startle in children with hyperekplexia. *Mov Disord* 2005; 20:484-489.
- Tijssen MA, Voorkamp LM, Padberg GW, van Dijk JG. Startle responses in hereditary hyperekplexia. *Arch Neurol* 1997; 54:388-393.
- Matsumoto J, Fuhr P, Nigro M, Hallett M. Physiological abnormalities in hereditary hyperekplexia. *Ann Neurol* 1992; 32:41-50.
- Krauss GL, Mathews GC. Similarities in Mechanisms and Treatments for Epileptic and Nonepileptic Myoclonus. *Epilepsy Curr* 2003; 3:19-21.
- Kumru H, Kofler M, Valls-Solé J, Portell E, Vidal J. Brainstem reflexes are enhanced following severe spinal cord injury and reduced by continuous intrathecal baclofen. *Neurorehabil Neural Repair* 2009; 23:921-927.